

Distribution and Effect of some Heavy Metals in Selected Organs and Tissues of Albino Rats Exposed to Vehicular Exhaust Fumes

¹*Ajayi O. A., ¹Idowu A. B., ²Eromosele C. O., ¹Dedeke G. A. and ¹Ademolu K. O.

¹Biological Sciences Department, University of Agriculture, P.M.B. 2240, Abeokuta, Nigeria; Chemical Sciences

²Department, University of Agriculture, P.M.B. 2240, Abeokuta, Nigeria

*Corresponding author; E- mail: femijayiscribe2002@yahoo.com; Phone: +234 803 478 4896

Abstract

Vehicular exhaust fume has been greatly implicated as one of the major environmental pollutants all over the world, especially in developing nations. A study was carried out to investigate heavy metals distribution and effect on the soft tissues of Albino rats placed in close proximity to busy roads in Abeokuta. A total of 45 rats were randomly allotted to 3 groups of fifteen rats each. Two groups were placed in close proximity to busy roads while the third group (Control) was kept in Forestry Nursery of the University of Agriculture, Abeokuta Ogun State for 8 weeks respectively. The various organs were removed, digested by standard procedures and analyzed for heavy metals (Fe, Cr, Mn, Zn, Pd and Co) with Atomic Absorption Spectrophotometry. The result show a significantly higher concentration of heavy metals (Fe, Mn, Zn, Pd and Co) ($p < 0.05$) in the lung, heart and liver tissues of the rats at busy roads compared to control. Histopathological examination of internal organs (heart, lung, kidney and liver) of rats at busy roads revealed histopathological damage as compared to the control. The results above indicated that vehicular exhaust fumes may have adverse physiological effects on the rats and hence humans living in close proximity to busy roads will be predisposed to automobile pollution.

Keywords: Albino rat, vehicular exhaust fumes, heavy metals.

Introduction

Heavy metals are chemical elements with specific gravity that is at least five times the specific gravity of water (Passow *et al.*, 1961; Hawkes, 1997). Examples of heavy metals commonly found in the environment include lead, cadmium, mercury, zinc, arsenic, bismuth etc. These metals are particularly dangerous because they tend to bio-accumulate in the body tissues and organs (Luckey *et al.*, 1975; Babalola *et al.*, 2005). Heavy metal exposure is a public concern in Nigeria due to the increasing evidence concerning the effect of these heavy metals on the cognitive development of the populace especially, the young ones (Abulude *et al.*, 2003). The number of people living in cities worldwide increased dramatically during the last part of the

20th century. According to Chirenje *et al.* (2003), more than a third of the world population lived in the cities.

In developing countries, the air quality crisis in cities is often attributed in large measures (40–80%) to vehicular emission. In Nigeria, the main source of lead pollution is through automobile exhaust because of the use of leaded petrol. Tetraethyl lead is commonly used as an anti-knocking additive to improve the quality of petrol in Nigeria and many other countries (Dioka *et al.*, 2004; Kamal and Kumar, 1998). However, tetraethyl lead, added as an antiknock agent, caused serious air pollution in urban areas (Davis, 1990).

It is indeed now a common knowledge that heavy metals including lead, cadmium, mercury are toxic with no beneficial effects to humans and wildlife (Tyler, 1981 and Borgmann, 1983). Lead compounds are the major pollutants emitted by automobiles. Approximately 90% of absorbed lead is reported to be stored in the bone with a half life of 600 - 3000 days. The remaining 10% is stored in soft tissues like kidney, liver and brain. The half life of lead in these tissues ranges from 40 - 50 days (Hawkes, 1997).

Lead impairs learning, memory and audio-visual functions in children. Toxic effects of lead also include Nephrotoxicity, Hepatotoxicity and Cardiovascular damage (Hawkes, 1997). The carcinogenic effect of lead has been receiving increasing attention. Research has shown that lead causes oxidative stress in the body by inducing the generation of free radicals thereby reducing the antioxidant defence system of the cells (Hawkes, 1997). Effect of lead on reproductive systems is also well documented. Lead causes sterility in males by damaging the germinal epithelium and also spermatocytes (Kamal and Kumar, 1998). In females, menstrual irregularities, preterm deliveries and still births have been reported (WHO, 1986).

This research work was carried out to examine tissue distribution of heavy metals in albino rats exposed to vehicular exhaust fumes. The result will shed more light on heavy metals distribution pattern in human beings exposed to lead.

Material and Methods

Animal

A total of 45 healthy albino rats weighing between 100 and 120 g were used consisting of 3 groups of fifteen rats each. Two groups were placed in close proximity to busy roads at Oke-llewo and Ijemo roads respectively in Abeokuta, Ogun State while the third group (Control) was kept in Forestry Nursery of the University of Agriculture, Abeokuta far away from traffic movement for 8 weeks respectively. The animals were first acclimatized for 7 days in the forestry nursery of the University of Agriculture, Abeokuta where they had free access to food and clean water before exposure. At the completion of the exposure period, the rats were sacrificed and the following organs were obtained (a) Liver (b) Heart (c) Lung.

Tissues and Organ Digestion

The organs were freeze dried and 1 g of each organ/tissue was grinded to fine powder and 5 ml HNO₃ was added in a clean test tube. The mixture in the test tubes was plugged with cotton

wool and it was left on the bench overnight to solubilize. On the second day, the digested sample was heated at 100°C in water bath for 20 min. It was allowed to cool after which 1 ml of hydrogen peroxide was added to each tube to prevent excessive foaming. It was allowed to stand on the bench overnight again. On the third day, the samples were heated again at 100°C for 1 h and allowed to cool at room temperature. It was thereafter diluted with distilled water to a final volume of 25 ml and stored in a 30 ml polyethylene bottle for later analysis by A.A.S.

Test for Accumulation of Heavy Metals in Organs

The vital organs including liver, lung and heart were analysed for chromium, cobalt, iron, manganese, lead and zinc by Atomic Absorption Spectrometry.

Histological Studies of Some Soft Tissues

The heart, lung, liver, kidney and spleen were collected from each group of sacrificed rats using standard method by Sumner and Sumner, (1968) and stored in 1% formalin in appropriately labelled bottles. The organs were thereafter dehydrated by passing them through increasing concentration of ethanol 50%, 70%, 90% and 100% one hour each this is to remove water from the tissues. The dehydrated organs were then cleared in three changes of xylene to remove excess alcohol from the tissues. The organs were thereafter impregnated in 3 changes of molten wax to remove xylene from the tissue to replace it with paraffin wax. The organs were embedded in molten wax and allowed to solidify. The block were mounted on the microtome and sectioned at 5 microns. Sectioned tissues were mounted on the slide placed on the hot plate to melt the wax. Staining of the tissues was done by following the procedure for haematoxylin and eosin staining method. The stained were thereafter observed under the compound microscope for observable aberrations and photomicrographs of the slide were taken.

Statistical Analysis

Data obtained were analyzed by one way analysis of variance (ANOVA) followed by Duncan's multiple range test (DMRT) using statistical software package (SPSS for Windows). The results were presented as Mean \pm SD. $P < 0.05$ were regarded as statistically significant.

Results and Discussion

The heavy metals composition of soft tissues sample varied with the type of soft tissues and locations as seen in Figure 1 to 3. The Zn, Co, Mn, Pd and Fe compositions were significantly higher in Ijemo road compared to Oke-Ilewo road and forestry nursery of the University of Agriculture, Abeokuta concentrations. The main reasons for numerical higher concentration of heavy metals in Ijemo road might be attributed to the exposure of vehicular exhaust fumes. This area of the city has high traffic congestion. In addition, the Albino rats had significantly longer exposure to vehicle exhaust fumes compared with other places.

A similar result was obtained by Abudule *et al.* (2006) with higher concentration of Pd and Co in busy road compared to non busy roads. Idrees (2009) observed a similar result of high concentration of Zn and Pd in busy roads. Vidhya (2007) obtained high concentration of Pd in busy road. A study by Ogunsola *et al.* (1994) from Nigeria has shown that traffic wardens have a

higher blood lead levels than controls and they also have reduced spirometric measurements than controls. Sofoluwe (1968), working in Lagos, Nigeria visited the homes of 98 children suffering from bronchiolitis and pneumonia and found that these patients had been exposed to high concentrations of carbon monoxide, nitrogen dioxide, sulphur dioxide and benzene. Heavy metal concentrations were observed in the control rats. A similar result was obtained by Babalola *et al.* (2005). The distribution of heavy metals in the organs from the blood is probable that some quantity of this metal was present in the food given to the animals. The calcium supplement in the feed contains traces of lead hence animals that graze on these contaminated feed will contain substantial amount of lead. The presence of heavy metals in the blood and tissues of the control rats that were not placed close to busy road can also be attributed to the factor mentioned above.

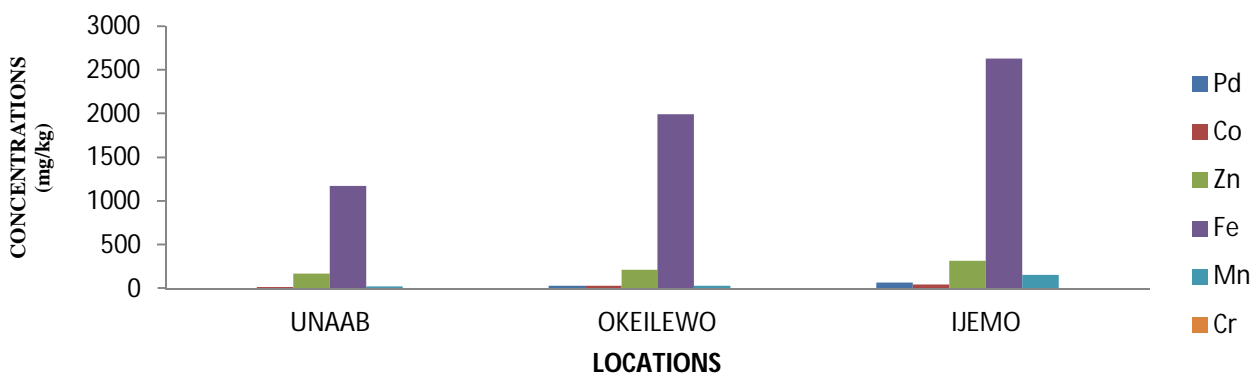


Fig.1. Variations of concentrations of metals in the Lungs of Albino rats among the three locations

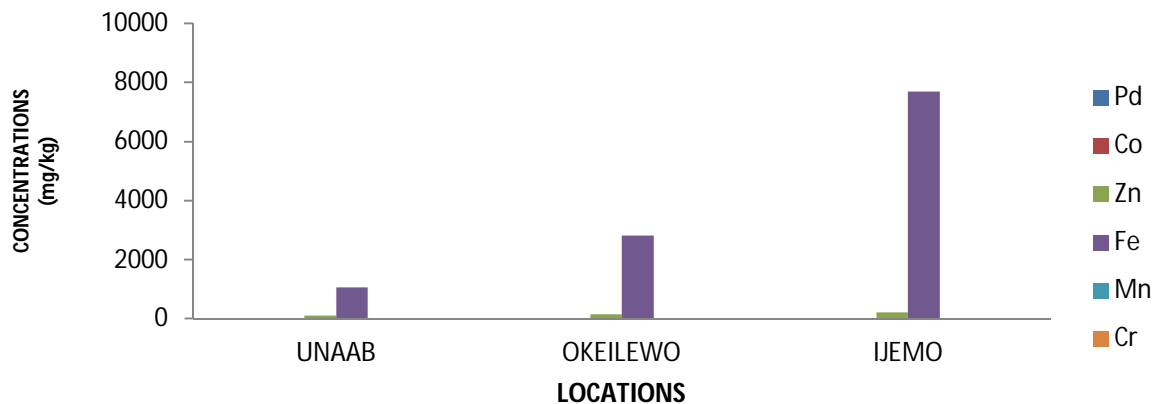

Fig.2. Variations of concentrations of metals in the Livers of Albino rats among the three locations

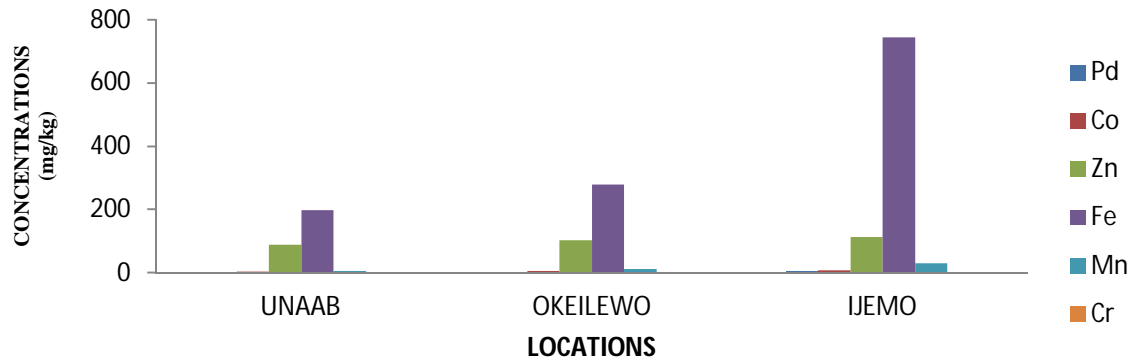


Fig.3. Variations of concentrations of metals in the Heart of Albino rats among the three locations

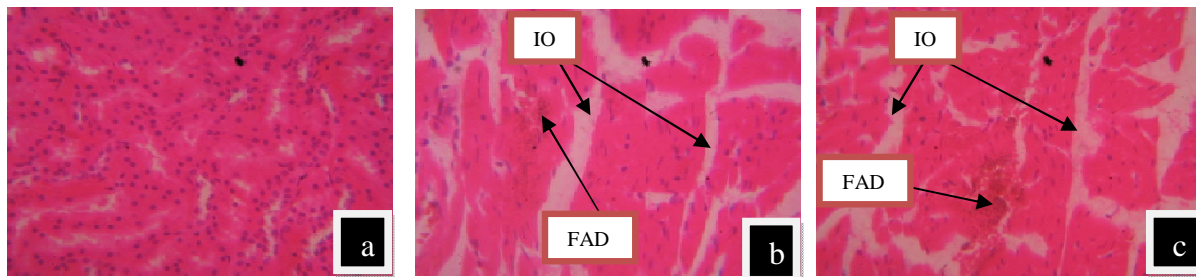


Plate 1 shows photomicrograph of heart section of rat: (a) at control showed normal appearance (H & E; X 350), (b) at Oke ilewo showing mild interstitial Oedema (IO) with focal area degeneration (FAD) (H & E; X 350) and (c) at Ijemo showing severe interstitial Oedema (IO) with focal area degeneration (FAD) (H & E; X 350).

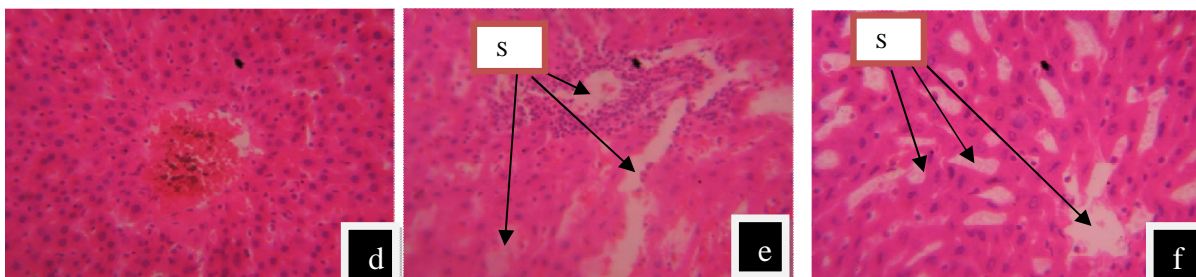


Plate 2 shows photomicrograph of liver section of rat: (d) at control showed normal appearance (H & E; X 350), (e) at Oke ilewo road showing mild focal area of periportal mononuclear Cellular infiltration with moderate sinusoidal dilation (SD) and (f) at Ijemo road showing mild focal area of periportal mononuclear Cellular infiltration with moderate sinusoidal dilation (SD).

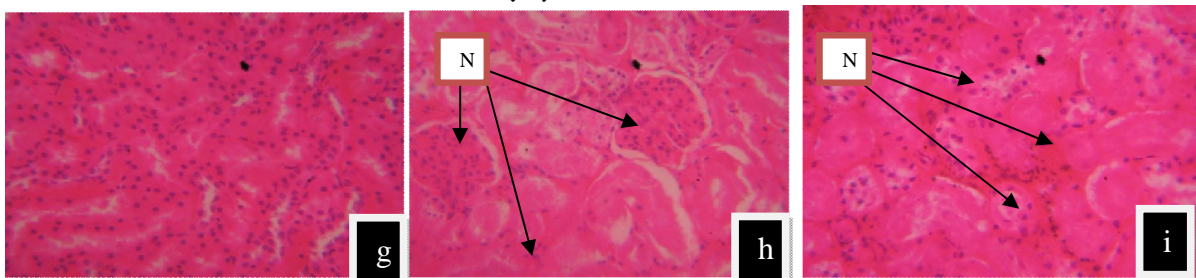


Plate 3 shows photomicrograph of the kidney section of rat: (g) at control showed normal appearance (H & E; x350), (h) rat at Ijemo showed mild tubular nephrosis (N) in the renal tubular epithelia (H & E; X350) and (i) rat at Oke-ilewo road showed mild tubular nephrosis (N) in the renal tubular epithelia (H & E; X350)

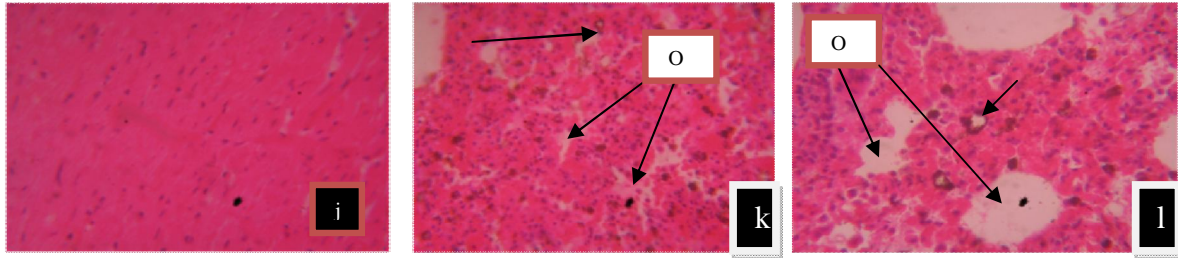


Plate 4 shows photomicrograph of the lung section of rat (j) at control showed normal appearance (H & E; x350), (k) at Oke Ilewo road showed mild Haemosiderosis (H) and oedema fluid (OF) (H & E ; x350) and (l) at Ijemo road showed diffuse haemosiderosis (H) and oedema Fluid (OF) (H & E ; x350)

There was significant pathological difference between the soft tissues of Albino rats exposed and unexposed to vehicular exhaust fumes. In the heart, diffuse interstitial oedema leading to degeneration of the myofibres was observed in the exposed rats but no significant change was observed in the heart of the unexposed rats. In the lung, diffuse thickened of the alveolar wall with red blood cells, oedema fluid and alveolar macrophages. Also, alveolar spaces filled with red blood cell and diffuse haemosiderosis with erythrophagocytosis were observed in the exposed rats but no significant change was observed in the lung of the unexposed rats. Kavita *et al.* (2010) reported a similar result when rats were exposed to diesel exhaust. He observed marked lymphocytes aggregation, oedematous changes in alveolar septa and bronchioles. Also, thickening of alveolar walls and small blood vessels were observed. The long-term exposure period induce the development of lung tumours (Ma and Ma, 2002).

In the kidney, diffuse tubular nephrosis in the renal tubular epithelail were observed in the exposed rats but no significant change was observed in the kidney of the unexposed rats. In the liver, showed focal areas of periportal mononuclear cellular infiltration with moderate diffuse sinusoidal dilation of the liver of Albino rats but no significant change was observed in the liver of the unexposed rats

Conclusion

The result of this study generally revealed the histological damage and presence of heavy metals in the soft tissues of Albino rats placed in close proximity to busy roads of Abeokuta cities. The level of the heavy metal at the moment is high enough to call for intervention by government agencies. The accumulation of heavy metals in the soft tissues of Albino rats along busy roads could be as a result continual usage of the road by vehicles driven with leaded petrol. This can also lead to serious health issues of human who live in cities. Indeed, vehicular exhaust fumes pollution need urgent control measure to reduce its menace on human population.

References

- Abulude, F.O., Akinjagunla, Y.S. and Omoniyi, A. (2006). An Investigation into the Effect of Vehicle Exhaust Fumes on the Level of Some Heavy Metals in Cows Blood. *Research Journal of Biological Sciences*. 1(1-4):9-11.
- Babalola, O.O., Ojo, L.O. and Aderemi, M.O. (2005). Lead levels in some biological samples of automechanics in Abeokuta, Nigeria. *Indian J. Biochem. Biophys.* 42: 401-403.
- Borgmann, U. (1983). 'Metal Speciation and Toxicity of Free Metal Ions to Aquatic Biota', In: J. O. Nriagu (ed), *Aquatic Toxicity, Advances in Environmental Science and Technology*, Vol. 13, John Wiley and Sons, New York, pp 47-73
- Chirenje, T., MA, L.O., Szulczewski, R., Littlell, K.M. and Zillioux, E. (2003). Arsenic distribution in Florida urban soils, *J. Evinron. Quality*, 109: 1-22.

- Davis, B. E. (1990). Heavy Metal in Soils. Blackie and Son Ltd., Glasgow and London.177-196.
- Dioka, C.E., Orisakwe, O.E., Adeniyi, F.A.A. and Meludu, S.C. (2004). Liver and Renal function tests in artisans occupationally exposed to Lead in Mechanic village in Newi, Nigeria. *Int. J. Environ. Res. Public Health* 1: 21-25.
- Hawkes, S.J. (1997). What is a heavy metal? *J. Chem. Edu.* 74: 1374-1378.
- Idrees F. A. (2009). Assessment of Trace Metal Distribution and Contamination in Surface Soils of Amman, Jordan. *Jordan Journal of Chemistry.* 4(1): 77-87.
- Kamala, K. and Kumar, B.D. (1998). Lead toxicity. *Indian Pediatr.* 35: 209-216. Kavita, G.,
- Basudeb, B., Shyam, B.L. and Arunabha, R. (2010). Effects of diesel exhaust, heavy metals and pesticides on various organ systems: Possible mechanisms and strategies for prevention and treatment. *Indian Journal of Experimental Biology.* 48:710-712.
- Luckey TD, Venugopal B, Hutchison D (1975). Heavy metal toxicity, safety and homology. *Qual. Suf. Thieme Stuttgart, Supplement*, 1: 120.
- Ma, J.Y and Ma, J.K. (2002). The dual effect of the particulate and organic components of diesel exhaust particles on the alteration of pulmonary immune/ inflammatory responses and metabolic enzymes. *J. Environ Sci Health c Environ Carcinog Ecotoxicol Rev.*20:17
- Ogunsola, O.J., Oluwole, A.F. and Asubiojo, O.I. (1994). Environmental impact of vehicular traffic in Nigeria; health aspects. *Sci. Total Environ.* **147**:111-6.
- Passow, H.A. Rothstein, H. and Clarkson ,T.W. (1961). The general pharmacology of the heavy metals. *Pharmacol. Rev.* 13: 185-225.
- Sofoluwe, G.O. (1968). Smoke pollution in dwellings of infants with bronchopneumonia. *Arch. Environ. Hlth.* **16**:670-672.
- Sumner, A T. and Sumner, B. E. H .(1969). A laboratory manual of Microtechnique and Histochemistry. Blackwell Scientific publication, Oxford. 85pp.
- Tyler, T. G. (1981). Heavy metals in soil biology and biochemistry. In: *Soil Biochemistry*, Marcel Dekker, New York, pp. 33.
- Vidhya, L., Dhandapani, M., Sekar, M. AND Mahimairaja, S. (2007). Lead pollution in soil, water and plants due to automobile emission in urban environments in Coimbatore. *Madras Agric. J.*, 94 (1-6): 89-96.
- WHO. (1986). Lead-environment Aspects environment health Criteria. 85: 2-4.